Journal of Cardiology (2012) 59, 132—138

Available online at www.sciencedirect.com

SciVerse ScienceDirect

journal homepage: www.elsevier.com/locate/jjcc

Review

Multifocal fibrosclerosis and IgG4-related disease involving the cardiovascular system

Nobukazu Ishizaka (MD, FJCC)[a,*], Aiko Sakamoto (MD)[b], Yasushi Imai (MD)[b], Fumio Terasaki (MD, FJCC)[a], Ryozo Nagai (MD, FJCC)[b]

[a] *Department of Cardiology, Osaka Medical College, Takatsuki-shi, Daigaku-machi 2-7, Osaka 569-8686, Japan*
[b] *Department of Cardiovascular Medicine, University of Tokyo Graduate School of Medicine, Tokyo, Japan*

Received 19 May 2011; received in revised form 12 October 2011; accepted 18 October 2011
Available online 3 December 2011

KEYWORDS
IgG-related sclerosing disease;
Chronic periaortitis;
Fibrosis;
Autoimmunity

Summary The cardiovascular system may be involved as a target organ of multifocal fibrosclerosis, which may manifest as idiopathic retroperitoneal fibrosis, inflammatory aortic aneurysm, inflammatory periarteritis, and inflammatory pericarditis. These pathological conditions can sometimes occur concomitantly. Idiopathic retroperitoneal fibrosis and inflammatory abdominal aortic aneurysm are both characterized by the presence of fibro-inflammatory tissue around the abdominal aorta expanding into the surrounding retroperitoneal structures, and together they may be termed 'chronic periaortitis'. Cardiovascular fibrosclerosis has become non-uncommonly encountered condition since imaging modalities have made its diagnosis more feasible. In addition, recent studies have demonstrated that a certain fraction, but not all, of cardiovascular fibrosclerosis may have a link with immunoglobulin-G4 (IgG4)-related sclerosing disease (IgG4-SD). IgG4-SD is histologically characterized by dense fibrosclerosis and infiltration of lymphocytes and IgG4-positive plasma cells, and these histopathologic findings seem to be essentially similar regardless of the organs involved. In this mini review, we summarize what is known so far about multifocal fibrosclerosis of the cardiovascular system and its association with IgG4-SD, and what remains to be clarified in future investigations.
© 2011 Japanese College of Cardiology. Published by Elsevier Ltd. All rights reserved.

Contents

Introduction 133
Chronic periaortitis 133
Clinical pictures of chronic periaortitis 133
Relationship between chronic periaortitis and IgG4-SD 134

* Corresponding author. Tel.: +81 72 683 1221; fax: +81 72 684 6533.
E-mail address: ishizaka@poh.osaka-med.ac.jp (N. Ishizaka).

0914-5087/$ — see front matter © 2011 Japanese College of Cardiology. Published by Elsevier Ltd. All rights reserved.
doi:10.1016/j.jjcc.2011.10.005

Thoracic periaortitis 134
Clinical pictures of thoracic periaortitis 134
Relationship between thoracic periaortitis and IgG4-SD 134
Inflammatory periarteritis — vasculitis of smaller size arteries 134
Clinical pictures of inflammatory periarteritis 134
Relationship between inflammatory periarteritis and IgG4-SD 136
Inflammatory pericarditis and IgG4-SD 136
Fibroinflammatory disorders of myocardium 136
Hurdles to overcome for further investigations 136
Conclusion 136
Acknowledgments 137
References 137

Introduction

Inflammatory and immune-mediated fibrosclerosis may involve various organs, including the cardiovascular system [1,2]. Immunoglobulin G4 (IgG4), which comprises about 4% of total immunoglobulin G (IgG), is unable to bind Clq complement and cannot activate the classic complement pathway [3]. Since Hamano et al. discovered the elevation of serum IgG4 levels and tissue infiltration of IgG4-positive plasma cells in autoimmune pancreatitis in 2001 [4,5], the relationship between IgG4-related immuno-inflammation and fibrosclerotic tissue degeneration has been gathering increasing attention [6,7], which is termed IgG4-related sclerosing disease (IgG4-SD) [8] or other synonyms [9]. IgG4-SD is now considered to encompass various organs including the lung [10], kidney [11], liver [12], and exocrinogical and endocrinological organs [13—15]. Regardless of the type of organs involved [16,17], the histopathologic findings of IgG4-SD seem to be essentially similar, which are characterized by dense fibrosclerosis, intense inflammatory cell infiltration with lymphocytes, IgG4-positive plasma cells, and scattered neutrophils and eosinophilic aggregates can also be observed [18]. In addition, IgG4-SD may appear as a mass-forming inflammatory pseudotumor [19,20].

A growing body of evidence suggests that the cardiovascular system may become a target of IgG4-related multifocal fibrosclerosis; it may be manifested as idiopathic retroperitoneal fibrosis, inflammatory aortic aneurysm, coronary periarteritis [21—23], and pericarditis [24]. In this mini review, we discuss briefly what is known about the cardiovascular manifestation of multifocal fibrosclerosis and its relationship with IgG4-related immuno-inflammatory conditions.

Chronic periaortitis

Inflammatory aortic aneurysm and idiopathic retroperitoneal fibrosis may be grouped together under the umbrella of chronic periaortitis according to their common histopathological features [22,25]. Although chronic periaortitis had been considered to be a relatively rare disorder, its presence has been increasingly recognized with the advent of non-invasive imaging modalities such as computed tomography (CT) scanning.

Clinical pictures of chronic periaortitis

Chronic periaortitis is commonly symptomatic at presentation, with the most frequent symptom being back and/or abdominal pain [26,27]. Abnormalities in inflammatory markers, such as elevated C-reactive protein and enhanced erythrocyte sedimentation rate, are common laboratory findings [28], and antinuclear antigen may be detected in about half of all cases [26,29]. Macroscopically, chronic periaortitis appears as a thick glistening retroperitoneal mass around the abdominal aorta or ileac arteries with a whitish surface [30]. Chronic periaortitis may be treated either medically or surgically. Corticosteroid and immunosuppressive drugs may be effective in the amelioration of radiological findings and in the reduction of inflammatory markers over a relatively short period [31].

Idiopathic retroperitoneal fibrosis, which is also called Ormond's disease [32], was first described by Albarran et al. in 1905 [33]. Retroperitoneal fibrosis may be caused by certain drugs, infections, radiotherapy, surgery, and malignancies [34]; however, more than two-thirds of cases are idiopathic in nature. Idiopathic retroperitoneal fibrosis has been considered to be an uncommon condition with an estimated incidence of 1.38 per 100,000 inhabitants [35]. Diagnosis of this disease relies primarily on imaging studies, most frequently CT scanning [26]; the disease is characterized by a fibroinflammatory soft tissue mass surrounding the aorta and/or adjacent tissues. Biopsy of the retroperitoneal mass is currently less frequently performed due to the potential risks; in some cases, however, the possibility of an alternative condition, such as malignancy or infection, should be ruled out histopathologically [36,37].

Inflammatory abdominal aortic aneurysm is a pathological condition that is estimated to account for less than 10% of all cases of abdominal aortic aneurysm [38,39]. Inflammatory abdominal aortic aneurysm may be termed the 'aneurysmal form of chronic periaortitis' and, when accompanied by ureteric blockade, 'perianeurysmal retroperitoneal fibrosis' [40], although these names have not been frequently used to date.

Relationship between chronic periaortitis and IgG4-SD

Neild et al. reported 12 patients with idiopathic retroperitoneal fibrosis which was diagnosed to be IgG4-related histologically and immunohistochemically [18]. In addition, Zen et al. reported 13 cases of idiopathic retroperitoneal fibrosis among 114 patients with histopathologically diagnosed IgG4-SD in a cross-sectional study [7]. Furthermore, Ito et al. reported a 77-year-old male patient who presented with malaise and intermittent lower abdominal pain and was diagnosed to have inflammatory aortic aneurysm which was shown to be IgG4-related immunohistochemically [41]. These findings indicate that chronic periaortitis may, at least in part, be IgG4-related.

Kasashima et al. identified 23 cases of inflammatory aneurysm whose diagnosis had been made on the basis of pathological findings from a total of 252 cases of surgically treated abdominal aortic aneurysm, and found that 13 cases (57%) were IgG4-related [42]. No clear differences were found between IgG4-related and non-IgG4-related inflammatory abdominal aortic aneurysms in terms of macroscopic findings in Kasashima et al.'s series. In addition, Sakata et al. compared the clinicopathologic characteristics of cases of inflammatory abdominal aortic aneurysm with age- and sex-adjusted cases of atherosclerotic abdominal aortic aneurysm [43]. They found that infiltration of IgG4-positive cell can occur in *atherosclerotic* aortic aneurysm, and that, conversely, not all cases of inflammatory abdominal aortic aneurysm are IgG4-related. Furthermore, we experienced a patient with idiopathic retroperitoneal fibrosis who had normal serum IgG4 levels (Fig. 1A) [44], and found that the clinical picture and response to corticoid treatment seemed to be similar between IgG4-related and non-IgG4-related idiopathic retroperitoneal fibrosis [45]. These observations indicate that not all the chronic periaortitis may be IgG4-related [46].

Thoracic periaortitis

Although the thoracic aorta has been considered relatively free from the inflammatory infiltration, several previous studies reported inflammatory aortic aneurysm or periaortitis at the thoracic aorta [47—50] (Fig. 1B).

Clinical pictures of thoracic periaortitis

Bahler et al. presented a case with fibroinflammatory soft mass paralleling the aortic arch, occurrence of which had been preceded by the onset of idiopathic retroperitoneal fibrosis by six years [51]. In addition, Gluhovschi et al. reported a 45-year female who presented with idiopathic retroperitoneal fibrosis causing renal dysfunction and thoracic periaortitis, both of which were ameliorated by immunosuppressive therapy [52]. It is suggested that thoracic periaortitis can be a manifestation of systemic fibrosclerosis.

Relationship between thoracic periaortitis and IgG4-SD

Some previous studies have investigated an association between thoracic aortic aneurysm/periaortitis and IgG4-related immuno-inflammation [16,53,54]. Kasashima et al. performed immunohistochemical analysis of the resected aorta from 125 patients of thoracic aortic aneurysm, and found five cases of IgG4-SD [55]; among them, one was diagnosed as *inflammatory* aneurysm and three were diagnosed as *atherosclerotic* aneurysm. Thus, the prevalence of IgG4-SD among thoracic aortic aneurysm/aortitis may be about 4% [55]. In Kasashima et al.'s series, mean age and sex-prevalence were similar between IgG4-related and non-IgG4-related thoracic aortic lesions; on the other hand, however, most of the IgG4-related thoracic lesions were located at the aortic arch, particularly in the distal arch, but only about one third of non-IgG4-related thoracic lesions were located at such regions. We recently reported a case of IgG4-related thoracic periaortitis at the aortic arch [54].

Stone et al. histologically analyzed 638 resected aortic samples obtained from thoracic aortitis cases, and reported that 33 (5.2%) were of a noninfectious nature [16]. In Stone et al.'s study, one of the cases of IgG4-related thoracic aortitis developed IgG4-SD involving liver, pancreas, and submandibular glands two years after aortic resection, suggesting that IgG4-related inflammatory thoracic aortitis may also represent a vascular manifestation of IgG4-related systemic fibrosclerosis. On the other hand, as in the case of abdominal aortic aneurysm [43], infiltration of IgG4-positive plasma cells or elevated serum IgG4 levels may not be a phenomenon exclusive to inflammatory aortic aneurysm/aortitis and, conversely, inflammatory aortic aneurysm/aortitis may not be always associated with these phenomena [56].

Inflammatory periarteritis — vasculitis of smaller size arteries

Development of fibrosclerosis and infiltration of inflammatory cell in the perivascular tissue may occur, albeit less frequently, in smaller-sized arteries [57,58], which may be termed inflammatory periarteritis [22].

Clinical pictures of inflammatory periarteritis

Mitchinson et al. reported two patients with ischemic heart disease in whom chronic coronary periarteritis was demonstrated histologically in conjunction with chronic periaortitis [21]. Maturen et al. have recently reported two patients with idiopathic retroperitoneal fibrosis who had perivascular low-attenuation soft tissue surrounding the coronary arteries, illustrated by CT, although significant luminal stenosis of the coronary artery was not noted at the site of periarteritis. [59] (Fig. 2). These findings suggest that coronary periarteritis may develop by the same pathological mechanisms as idiopathic retroperitoneal fibrosis.

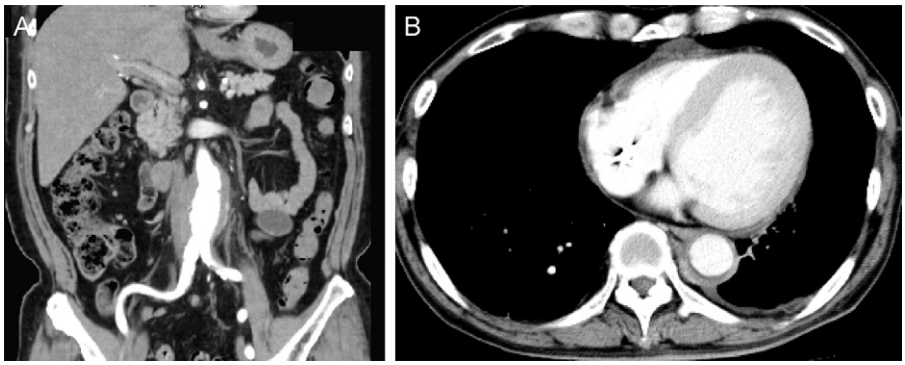

Fig. 1 Contrast enhanced computed tomography of chronic periaortitis. (A) Retroperitoneal fibrosis in a reported case [44]. (B) Thoracic periaortitis in a reported case [69].

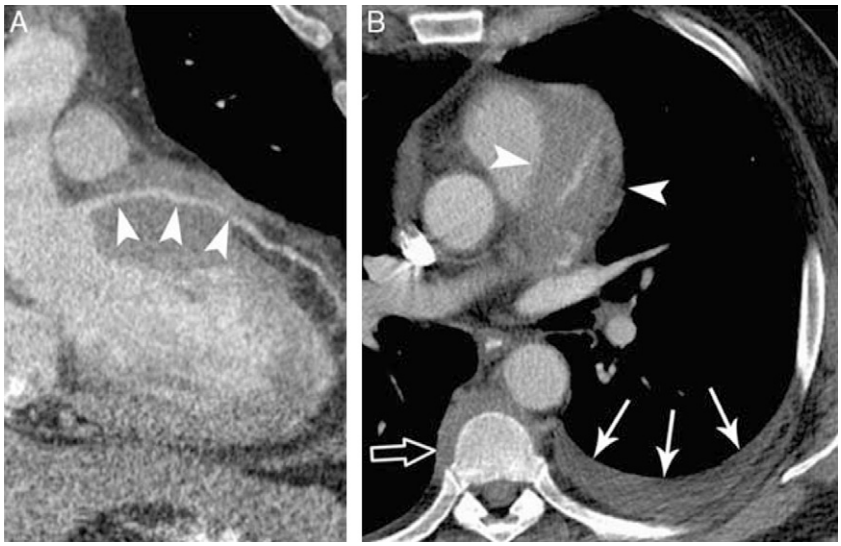

Fig. 2 Contrast enhanced computed tomography of a case of idiopathic retroperitoneal fibrosis. (A) Abnormal soft tissue encasing normal diameter left main (white arrowheads) and proximal left anterior descending coronary arteries can be seen. (B) Axial image showing the abnormal soft tissue surrounding coronary arteries (white arrowheads), right paraspinal mass (open arrow), and left pleural effusion (white arrows). Reproduced from Maturen et al. [59].

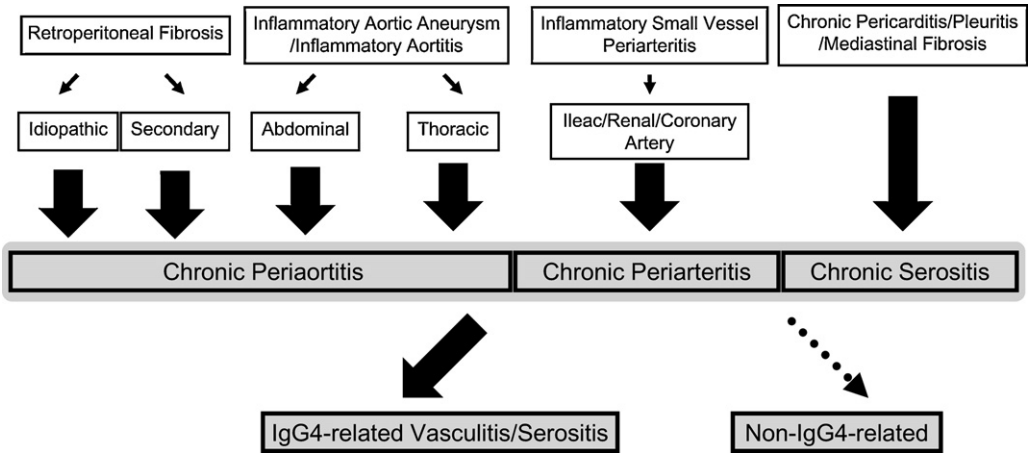

Fig. 3 Proposed scheme of chronic vasculitis/serositis. This clinical entity may have to be reorganized according to the underlying immunopathological background.

Relationship between inflammatory periarteritis and IgG4-SD

Inoue et al. demonstrated 17 cases of inflammatory periaortitis or periarteritis that had occurred in the superior mesenteric, inferior mesenteric, and splenic arteries [60], and histologic examination of which, when available, revealed irregular fibrosis in the arterial walls and diffuse infiltration of IgG4-positive cells within the inflamed areas. In addition, Matsumoto et al. presented a case of IgG4-related abdominal periaortitis and inflammatory coronary periarteritis, manifested as a tumorous mass around the coronary artery [17]. Furthermore, we have recently experienced a patient with IgG4-related periarteritis of the coronary artery who was admitted to our hospital owing to the chest symptoms [23]. In this patient, serum IgG4 levels were elevated at 564 mg/dL, and a glittery white-yellowish elastic-hard periarterial mass surrounding the left circumflex artery could be seen after the incision of the pericardium. Whether IgG4-related coronary periarteritis plays a role in the development of coronary artery stenosis remains to be investigated, however, we may have to be, at least, aware that coronary periarteritis may increasingly be diagnosed in the era of multi-detector coronary-CT angiography.

Inflammatory pericarditis and IgG4-SD

Several reports have demonstrated inflammatory pericardial fibrosis that occurred as a manifestation of systemic multifocal fibrosclerosis [2,24]. Sugimoto et al. reported a 68-year-old man who showed constrictive pericarditis as the initial manifestation, and staining of the excised pericardium with anti-IgG4 antibody revealed the infiltration of IgG4-positive plasma cell [61]. This patient developed pleural effusion and progressive pleural fibrosis six months after post-pericardiostomy. We have recently reported an 83-year-old man with pericardial fibrosis who died from cardio-respiratory failure due to massive pericardial effusion, and autopsy showed the infiltration of IgG4-positive plasma cells in the pericardium, as well as in the visceral and parietal pleura, pancreas, and retroperitoneal fibrous tissues [45]. This patient had a past history of autoimmune pancreatitis. These observations were consistent with the notion that inflammatory pericarditis may also develop as a feature of IgG4-related multifocal fibrosclerosis.

Fibroinflammatory disorders of myocardium

Whether IgG4-related immuno-inflammation may underlie myocardial fibrosclerosis that would lead to cardiac failure seems to have been least extensively studied [62,63]. Cardiac sarcoidosis may be one of the disorders associated with the infiltration of lymphocytic cells and development of fibrosis in the heart [64]. We investigated the relationship between IgG4-SD and cardiac sarcoidosis; however, we could not find a meaningful relationship between these conditions [65]. Whether IgG4-related immuno-inflammation would underlie the pathogenesis of other myocardial disorders causing fibrosis and cardiac failure should be assessed in further studies.

Hurdles to overcome for further investigations

As discussed above, IgG4-related autoimmunity may, although not always, underlie multifocal fibrosclerosis in the cardiovascular system. Toward achieving optimal therapeutic strategies and better understanding of the pathophysiology of IgG4-related fibrosclerosis in the cardiovascular system, there is an increasing need for research in this field; however, there are several hurdles to overcome before advances can be made.

First, the definition, as well as the nomenclature, of the disorder. Inflammatory aortic aneurysm is said to be present when periaortic fibrosis coexists with dilatation of the aorta; however, the cut-off value of aortic diameter that discriminates between idiopathic retroperitoneal fibrosis and inflammatory abdominal aortic aneurysm does not seem to be clear [34], or may sometimes be impractical. Likewise, retroperitoneal fibrosis may be subclassified as *IgG4-related* and *non-IgG4-related* forms; alternatively, however, it may also be subclassified as *idiopathic* and *secondary* forms. Furthermore, because IgG4-related fibrosclerosis can also occur in small-size vessels, pericardium, and possibly pleura, it might more suitably be termed 'IgG4-related (peri)vasculitis/serositis' (Fig. 3).

Second, differential diagnosis. In infected, or mycotic, aortic aneurysm, the bacterial culture may be negative in half of all cases [66] and serum IgG4 levels might be elevated [67]. Considering that about half of all cases of inflammatory aortic aneurysm may be IgG4-related [29], these situations may make differential diagnosis between inflammatory and infected aneurysm difficult. In addition, it should also be noted that diagnosis of IgG4-related or non-IgG4-related multifocal fibrosclerosis should not be made solely depending on the responsiveness to medical therapy, because some types of malignancy that might underlie or be misdiagnosed as fibrosclerotic disorders may also respond to corticosteroid therapy [68]. In patients with multiorgan fibrosis, we should not overlook the possibility of malignant disease.

Third, IgG4 positivity. Clinical pictures and therapeutic responsiveness of non-IgG4-related fibrosclerosis may be similar, sometimes almost identical, to IgG4-SD. It is possible that IgG4-positive cell infiltration may be a transient phenomenon during the development of fibrosclerotic tissue degeneration and that IgG4 may not play a central, but rather a bystander, role in the lesion formation.

Conclusion

The cardiovascular system may be one of the target organs of IgG4-related, and non-IgG4-related, systemic multifocal fibrosclerosis. Cardiologists should be aware of this clinicopathological condition, not only because it can be potently managed by corticosteroid and/or immunosuppressive therapies, but also because it can take a rapid and fatal clinical course [45]. In addition, caution should be applied because cardiovascular fibrosclerosis may be accompanied by or misdiagnosed from other co-morbidities such as infection and malignancy. Further research is warranted in the field of IgG4-related cardiovascular fibrosclerosis.

Acknowledgments

The work was supported in part by Health Sciences Research Grants of The Ministry of Health, Labour and Welfare of Japan (Research on Hepatitis, Acute Aortic Syndrome), Grants from Meiji Yasuda Life Foundation of Health and Welfare, Mitsui Life Social Welfare Foundation, and the Japan Society for the Promotion of Science (JSPS) through its ''Funding Program for World-Leading Innovative R&D on Science and Technology (FIRST Program).''

References

[1] Sassa H, Kondo J, Tsuboi H, Sone T, Tsubone M. A case of idiopathic retroperitoneal fibrosis with chronic pericarditis. Intern Med 1992;31:414—7.
[2] Baur M, Hulla W, Kienzer H, Klimpfinger M, Dittrich C. Pericarditis as the initial manifestation of retroperitoneal fibrosis — a case report. Wien Med Wochenschr 2002;152:230—2.
[3] van der Zee JS, van Swieten P, Aalberse RC. Inhibition of complement activation by IgG4 antibodies. Clin Exp Immunol 1986;64:415—22.
[4] Hamano H, Kawa S, Horiuchi A, Unno H, Furuya N, Akamatsu T, Fukushima M, Nikaido T, Nakayama K, Usuda N, Kiyosawa K. High serum IgG4 concentrations in patients with sclerosing pancreatitis. N Engl J Med 2001;344:732—8.
[5] Hamano H, Kawa S, Ochi Y, Unno H, Shiba N, Wajiki M, Nakazawa K, Shimojo H, Kiyosawa K. Hydronephrosis associated with retroperitoneal fibrosis and sclerosing pancreatitis. Lancet 2002;359:1403—4.
[6] Smyrk TC. Pathological features of IgG4-related sclerosing disease. Curr Opin Rheumatol 2011;23:74—9.
[7] Zen Y, Nakanuma Y. IgG4-related disease: a cross-sectional study of 114 cases. Am J Surg Pathol 2010;34:1812—9.
[8] Van Moerkercke W, Verhamme M, Doubel P, Meeus G, Oyen R, Van Steenbergen W. Autoimmune pancreatitis and extrapancreatic manifestations of IgG4-related sclerosing disease. Acta Gastroenterol Belg 2010;73:239—46.
[9] Okazaki K, Uchida K, Koyabu M, Miyoshi H, Takaoka M. Recent advances in the concept and diagnosis of autoimmune pancreatitis and IgG4-related disease. J Gastroenterol 2011;46:277—88.
[10] Takato H, Yasui M, Ichikawa Y, Fujimura M, Nakao S, Zen Y, Minato H. Nonspecific interstitial pneumonia with abundant IgG4-positive cells infiltration, which was thought as pulmonary involvement of IgG4-related autoimmune disease. Intern Med 2008;47:291—4.
[11] Saeki T, Saito A, Hiura T, Yamazaki H, Emura I, Ueno M, Miyamura S, Gejyo F. Lymphoplasmacytic infiltration of multiple organs with immunoreactivity for IgG4: IgG4-related systemic disease. Intern Med 2006;45:163—7.
[12] Umemura T, Zen Y, Hamano H, Ichijo T, Kawa S, Nakanuma Y, Kiyosawa K. IgG4 associated autoimmune hepatitis: a differential diagnosis for classical autoimmune hepatitis. Gut 2007;56:1471—2.
[13] Yamamoto M, Takahashi H, Sugai S, Imai K. Clinical and pathological characteristics of Mikulicz's disease (IgG4-related plasmacytic exocrinopathy). Autoimmun Rev 2005;4:195—200.
[14] Leporati P, Landek-Salgado MA, Lupi I, Chiovato L, Caturegli P. IgG4-related hypophysitis: a new addition to the hypophysitis spectrum. J Clin Endocrinol Metab 2011;96:1971—80.
[15] Dahlgren M, Khosroshahi A, Nielsen GP, Deshpande V, Stone JH. Riedel's thyroiditis and multifocal fibrosclerosis are part of the IgG4-related systemic disease spectrum. Arthritis Care Res (Hoboken) 2010;62:1312—8.
[16] Stone JH, Khosroshahi A, Deshpande V, Stone JR. IgG4-related systemic disease accounts for a significant proportion of thoracic lymphoplasmacytic aortitis cases. Arthritis Care Res (Hoboken) 2010;62:316—22.
[17] Matsumoto Y, Kasashima S, Kawashima A, Sasaki H, Endo M, Kawakami K, Zen Y, Nakanuma Y. A case of multiple immunoglobulin G4-related periarteritis: a tumorous lesion of the coronary artery and abdominal aortic aneurysm. Hum Pathol 2008;39:975—80.
[18] Neild GH, Rodriguez-Justo M, Wall C, Connolly JO. Hyper-IgG4 disease: report and characterisation of a new disease. BMC Med 2006;4:23.
[19] Zen Y, Kitagawa S, Minato H, Kurumaya H, Katayanagi K, Masuda S, Niwa H, Fujimura M, Nakanuma Y. IgG4-positive plasma cells in inflammatory pseudotumor (plasma cell granuloma) of the lung. Hum Pathol 2005;36:710—7.
[20] Zen Y, Fujii T, Sato Y, Masuda S, Nakanuma Y. Pathological classification of hepatic inflammatory pseudotumor with respect to IgG4-related disease. Mod Pathol 2007;20:884—94.
[21] Mitchinson MJ, Wight DG, Arno J, Milstein BB. Chronic coronary periarteritis in two patients with chronic periaortitis. J Clin Pathol 1984;37:32—6.
[22] Mitchinson MJ. Chronic periaortitis and periarteritis. Histopathology 1984;8:589—600.
[23] Tanigawa J, Daimo M, Murai M, Katsumata T, Tsuji M, Ishizaka N. IgG4-related coronary periarteritis in patients presenting with myocardial ischemia. Hum Pathol, in press.
[24] Omura Y, Yoshioka K, Tsukamoto Y, Maeda I, Morikawa T, Konishi Y, Inoue T, Sato T. Multifocal fibrosclerosis combined with idiopathic retro-peritoneal and pericardial fibrosis. Intern Med 2006;45:461—4.
[25] Vaglio A, Buzio C. Chronic periaortitis: a spectrum of diseases. Curr Opin Rheumatol 2005;17:34—40.
[26] Kermani TA, Crowson CS, Achenbach SJ, Luthra HS. Idiopathic retroperitoneal fibrosis: a retrospective review of clinical presentation, treatment, and outcomes. Mayo Clin Proc 2011;86:297—303.
[27] Yin MD, Zhang J, Wang SY, Duan ZQ, Xin SJ. Inflammatory abdominal aortic aneurysm: clinical features and long term outcome in comparison with atherosclerotic abdominal aortic aneurysm. Chin Med J 2010;123:1255—8.
[28] Vaglio A, Corradi D, Manenti L, Ferretti S, Garini G, Buzio C. Evidence of autoimmunity in chronic periaortitis: a prospective study. Am J Med 2003;114:454—62.
[29] Kasashima S, Zen Y, Kawashima A, Konishi K, Sasaki H, Endo M, Matsumoto Y, Kawakami K, Kasashima F, Moriya M, Kimura K, Ohtake H, Nakanuma Y. Inflammatory abdominal aortic aneurysm: close relationship to IgG4-related periaortitis. Am J Surg Pathol 2008;32:197—204.
[30] Yoshizaki T, Tabuchi N, Makita S. Inferior vena cava occlusion secondary to an inflammatory abdominal aortic aneurysm. Interact Cardiovasc Thorac Surg 2007;6:128—9.
[31] Adler S, Lodermeyer S, Gaa J, Heemann U. Successful mycophenolate mofetil therapy in nine patients with idiopathic retroperitoneal fibrosis. Rheumatology (Oxford) 2008;47:1535—8.
[32] Ormond JK. Bilateral ureteral obstruction due to envelopment and compression by an inflammatory retroperitoneal process. J Urol 1948;59:1072—9.
[33] Albarran J. Rétention rénale par périurétérite. Libération externe de l'uretére. Assoc Fr Urol 1905;9:511—7.
[34] Vaglio A, Salvarani C, Buzio C. Retroperitoneal fibrosis. Lancet 2006;367:241—51.
[35] Uibu T, Oksa P, Auvinen A, Honkanen E, Metsarinne K, Saha H, Uitti J, Roto P. Asbestos exposure as a risk factor for retroperitoneal fibrosis. Lancet 2004;363:1422—6.
[36] Koep L, Zuidema GD. The clinical significance of retroperitoneal fibrosis. Surgery 1977;81:250—7.

[37] Chim CS, Liang R, Chan AC. Sclerosing malignant lymphoma mimicking idiopathic retroperitoneal fibrosis: importance of clonality study. Am J Med 2001;111:240—1.
[38] Sasaki S, Yasuda K, Takigami K, Yamauchi H, Shiiya N, Sakuma M. Inflammatory abdominal aortic aneurysms and atherosclerotic abdominal aortic aneurysms — comparisons of clinical features and long-term results. Jpn Circ J 1997;61:231—5.
[39] Yusuf K, Murat B, Unal A, Ulku K, Taylan K, Ozerdem O, Erdal Y, Tahsin Y. Inflammatory abdominal aortic aneurysm: predictors of long-term outcome in a case-control study. Surgery 2007;141:83—9.
[40] Serra RM, Engle JE, Jones RE, Schoolwerth AC. Perianeurysmal retroperitoneal fibrosis. An unusual cause of renal failure. Am J Med 1980;68:149—53.
[41] Ito H, Kaizaki Y, Noda Y, Fujii S, Yamamoto S. IgG4-related inflammatory abdominal aortic aneurysm associated with autoimmune pancreatitis. Pathol Int 2008;58:421—6.
[42] Kasashima S, Zen Y, Kawashima A, Endo M, Matsumoto Y, Kasashima F. A new clinicopathological entity of IgG4-related inflammatory abdominal aortic aneurysm. J Vasc Surg 2009;49:1264—71.
[43] Sakata N, Tashiro T, Uesugi N, Kawara T, Furuya K, Hirata Y, Iwasaki H, Kojima M. IgG4-positive plasma cells in inflammatory abdominal aortic aneurysm: the possibility of an aortic manifestation of IgG4-related sclerosing disease. Am J Surg Pathol 2008;32:553—9.
[44] Sakamoto A, Okamoto K, Ishizaka N, Tejima K, Hirata Y, Nagai R. 18F-fluorodeoxyglucose positron emission tomography in a case of retroperitoneal fibrosis. Int Heart J 2006;47:645—50.
[45] Sakamoto A, Nagai R, Saito K, Imai Y, Takahashi M, Hosoya Y, Takeda N, Fujihara M, Hirano K, Koike K, Enomoto Y, Kume H, Homma Y, Maeda D, Yamada H, et al. Idiopathic retroperitoneal fibrosis, inflammatory aortic aneurysm, and inflammatory pericarditis — retrospective analysis of 11 case histories. J Cardiol 2012;59:139—46.
[46] Zen Y, Onodera M, Inoue D, Kitao A, Matsui O, Nohara T, Namiki M, Kasashima S, Kawashima A, Matsumoto Y, Katayanagi K, Murata T, Ishizawa S, Hosaka N, Kuriki K, et al. Retroperitoneal fibrosis: a clinicopathologic study with respect to immunoglobulin G4. Am J Surg Pathol 2009;33:1833—9.
[47] Crawford JL, Stowe CL, Safi HJ, Hallman CH, Crawford ES. Inflammatory aneurysms of the aorta. J Vasc Surg 1985;2:113—24.
[48] Okita Y, Takamoto S, Ando M, Kawashima Y, Matsuo H. A case report of inflammatory aneurysm of the thoracic aorta. J Vasc Surg 1995;21:999—1001.
[49] Roth M, Lemke P, Bohle RM, Klovekorn WP, Bauer EP. Inflammatory aneurysm of the ascending thoracic aorta. J Thorac Cardiovasc Surg 2002;123:822—4.
[50] Palmisano A, Vaglio A. Chronic periaortitis: a fibroinflammatory disorder. Best Pract Res Clin Rheumatol 2009;23:339—53.
[51] Bahler C, Hammoud Z, Sundaram C. Mediastinal fibrosis in a patient with idiopathic retroperitoneal fibrosis. Interact Cardiovasc Thorac Surg 2008;7:336—8.
[52] Gluhovschi G, Bozdog G, Miclaus G, Puscasiu T, Gluhovschi C, Bob F, Velciov S, Petrica L, Trandafirescu V, Gadalean F. Idiopathic retroperitoneal fibrosis with particular perirenal and intrarenal extension associated with left renal artery stenosis. The atheromatous periaortitis with retroperitoneal fibrosis suggests a pathogenic relationship between atherosclerosis and fibrosis? Wien Klin Wochenschr 2011;123:124—8.
[53] Ishida M, Hotta M, Kushima R, Asai T, Okabe H. IgG4-related inflammatory aneurysm of the aortic arch. Pathol Int 2009;59:269—73.
[54] Takahashi M, Shimizu T, Inajima T, Hosoya Y, Takeda N, Ishizaka N, Yamashita H, Hirata Y, Nagai R. A case of localized IgG4-related thoracic periarteritis and recurrent nerve palsy. Am J Med Sci 2011;341:166—9.
[55] Kasashima S, Zen Y, Kawashima A, Endo M, Matsumoto Y, Kasashima F, Ohtake H, Nakanuma Y. A clinicopathologic study of immunoglobulin G4-related sclerosing disease of the thoracic aorta. J Vasc Surg 2010;52:1587—95.
[56] Miyashita T, Yoshioka K, Shibata M, Kasamatsu Y, Nakamura T, Motoki M, Kato M, Hattori K, Shibata T, Yamagami K. Endovascular repair of sealed rupture of a thoracic inflammatory aneurysm that developed after corticosteroid therapy. Intern Med 2010;49:1221—4.
[57] Salvarani C, Calamia KT, Matteson EL, Hunder GG, Pipitone N, Miller DV, Warrington KJ. Vasculitis of the gastrointestinal tract in chronic periaortitis. Medicine (Baltimore) 2011;90:28—39.
[58] Scheel Jr PJ, Feeley N. Retroperitoneal fibrosis: the clinical, laboratory, and radiographic presentation. Medicine (Baltimore) 2009;88:202—7.
[59] Maturen KE, Sundaram B, Marder W, Swartz RD. Coronary artery involvement in idiopathic retroperitoneal fibrosis: computed tomographic findings. J Thorac Imaging 2011 [Epub ahead of print].
[60] Inoue D, Zen Y, Abo H, Gabata T, Demachi H, Yoshikawa J, Miyayama S, Nakanuma Y, Matsui O. Immunoglobulin G4-related periaortitis and periarteritis: CT findings in 17 patients. Radiology 2011;261:625—33.
[61] Sugimoto T, Morita Y, Isshiki K, Yamamoto T, Uzu T, Kashiwagi A, Horie M, Asai T. Constrictive pericarditis as an emerging manifestation of hyper-IgG4 disease. Int J Cardiol 2008;130: e100—1.
[62] Kawai S, Okada R. Interstitial cell infiltrate and myocardial fibrosis in dilated cardiomyopathy: a special type of cardiomegaly corresponding to sequelae of myocarditis. Heart Vessels 1990;5:230—6.
[63] Maehashi N, Yokota Y, Takarada A, Usuki S, Maeda S, Yoshida H, Sugiyama T, Fukuzaki H. The role of myocarditis and myocardial fibrosis in dilated cardiomyopathy. Analysis of 28 necropsy cases. Jpn Heart J 1991;32:1—15.
[64] Okura Y, Dec GW, Hare JM, Kodama M, Berry GJ, Tazelaar HD, Bailey KR, Cooper LT. A clinical and histopathologic comparison of cardiac sarcoidosis and idiopathic giant cell myocarditis. J Am Coll Cardiol 2003;41:322—9.
[65] Terasaki F, Kizawa H, Fujita S, Kanzaki Y, Kitaura Y, Ishizaka N. Assessment of serum IgG4 levels in cardiac and non-cardiac sarcoidosis. Hum Pathol, doi:10.1016/j.humpath.2011.07.002.
[66] Bennett DE. Primary mycotic aneurysms of the aorta. Report of case and review of the literature. Arch Surg 1967;94: 758—65.
[67] Kanemitsu S, Shimono T, Nakamura A, Yamamoto K, Wada H, Shimpo H. Molecular diagnosis of nonaneurysmal infectious aortitis. J Vasc Surg 2011;53:472—4.
[68] Takahashi N, Ghazale AH, Smyrk TC, Mandrekar JN, Chari ST. Possible association between IgG4-associated systemic disease with or without autoimmune pancreatitis and non-Hodgkin lymphoma. Pancreas 2009;38:523—6.
[69] Amiya E, Ishizaka N, Watanabe A, Endo Y, Itou R, Yoshida S, Nangaku M, Nagai R. Retroperitoneal fibrosis with periaortic and pericardial involvement. Circ J 2005;69:760—2.